Type II Endoleaks, Left-Arm Complications, and Need of Revascularization after Left Subclavian Artery Coverage for Thoracic Aortic Aneurysms Endovascular Repair: A Systematic Review

Sergio Quilici Belczak,[1] Erasmo Simão Silva,[1] Rafael Klajner,[2] Pedro Puech-Leão,[1] and Nelson De Luccia,[1] São Paulo, Sao Paulo, Brazil

Background: The status of the left arm, the need of revascularization, and the occurrence of type II endoleakes from de left subclavian artery (LSA) after intention LSA coverage for thoracic aortic aneurysm endovascular repair need to be better understood. This systematic review was developed for contributing with such issue.

Methods: Systematic literature review of studies published from January 2000 through December 2015 identified 7 studies comprising 201 patients submitted to elective endovascular repair for thoracic aortic aneurysms requiring intentional LSA coverage. Outcomes of interest included left-arm complications (ischemia, symptoms of claudication, and subclavian steal syndrome [SSS]) requiring postoperative revascularization of LSA, as well as endoleaks from the subclavian artery requiring postoperative embolization of LSA.

Results: Left-arm complication rate was 4.5% (9 patients), requiring postoperative revascularization of LSA in 1 case (0.5%) of SSS. Type II endoleaks from the subclavian artery requiring postoperative embolization of LSA were reported in 2 cases (1.0%).

Conclusions: Low-quality evidence suggests very low rates of arm complications with need of LSA revascularization and of type II endoleaks requiring embolization in elective endovascular treatment of thoracic aortic aneurysms with intentional coverage of LSA without prophylactic revascularization of LSA.

INTRODUCTION

Endovascular repair has become the preferred treatment for thoracic aortic aneurysms for selected cases since it was firstly reported in 1988[1,2] and has been associated with decreased short-term morbidity and mortality when compared to open repair. This treatment modality can require partial or complete intentional coverage of the left subclavian artery (LSA), so that an adequate proximal landing zone can be achieved.

To avoid some downstream ischemic complications consequent to coverage of the LSA, some authors defend the prophylactic revascularization of the LSA before stent graft deployment,[3,4] whereas others do not encourage such prophylactic procedure except for very selected cases.[5–9] There are still others who observed low risks associated with simply covering the LSA and reserve revascularization of the subclavian artery only if left arm claudication, vertebrobasilar insufficiency, or other similar symptoms develop in patients after treatment.[10–12]

Ischemic complications associated with coverage of the LSA include posterior circulation stroke, spinal cord ischemia (SCI), and left-arm ischemia or claudication. There are many articles[13–17] and

[1]*Department of Vascular Surgery, School of Medicine, São Paulo University, São Paulo, SP, Brazil.*

[2]*Department of Vascular Surgery, São Camilo University, São Paulo, SP, Brazil.*

Correspondence to: Sergio Quilici Belczak, Department of Vascular Surgery, School of Medicine, São Paulo University, Rua Mato Grosso 306/609, 01239-040 São Paulo, SP, Brazil; E-mail: belczak@gmail.com

Ann Vasc Surg 2017; 41: 294–299
http://dx.doi.org/10.1016/j.avsg.2016.08.049

Manuscript received: June 9, 2016; manuscript accepted: August 16, 2016; published online: 27 February 2017

relevant systematic reviews[18–22] dealing with stroke and SCI after LSA coverage, generally regarding thoracic pathologies all together. On the other hand, there are few studies and apparently no reviews focusing left arm malperfusion after coverage of the LSA during thoracic aortic aneurysms repair leading to the necessity of postoperative LSA revascularization.

Type II endoleaks from the LSA after thoracic endografting with coverage of LSA was considered benign at first, but more recently continued aneurysm sac expansion has been observed in the presence of this type of endoleaks.[23] The rates of type II endoleaks range from 0% to about 8%,[24] but its treatment has been successful in the great part of reported cases.[24–26]

In this systematic review, we analyze data from the literature about the status of the left arm and need of revascularization as well as the occurrence of type II endoleaks from the LSA and its treatment after LSA coverage for thoracic aortic aneurysms endovascular repair.

MATERIAL AND METHODS

Literature Search

The literature search was performed using MEDLINE, PubMed, Embase, and Cochrane databases for all relevant studies published in English between January 2000 and December 2015. The MeSH search headings ''aorta, thoracic/aneurysms'', ''TEVAR'', ''subclavian artery coverage'', ''complications'', and ''endoleaks'' were used in combination with the operators AND/OR. The search was extended by using the ''related articles'' function and the reference lists of the articles identified in the initial search. All abstracts were reviewed for a first selection of the eligible studies.

Review articles, case reports, and editorials were excluded. As to articles reporting the same sample, it were included the more recent ones. All full remaining articles were carefully reviewed. New exclusions included studies with only emergent/urgent procedures, reported results involving different thoracic aortic pathologies without separating the results related specifically to the aneurysms, and lack of description of left-arm complications.

Data Extraction

Data from each study were extracted by 2 reviewers regarding authors and year of publication, study design, number of patients studied, number of LSA covered, number of prophylactic revascularizations of LSA, and outcomes.

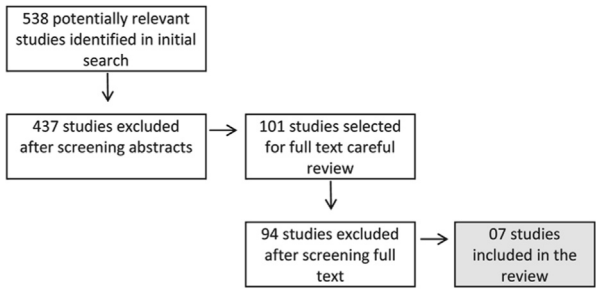

Fig. 1. Study identification strategy.

Outcomes included left-arm complications, as ischemia, symptoms of claudication, and subclavian steal syndrome (SSS) requiring postoperative revascularization of LSA, as well as endoleaks from the subclavian artery requiring postoperative embolization of LSA.

Data Analysis

Data were recorded and tabulated with Microsoft Excel® software. Emphasis was placed in a descriptive report, due to the small number of studies and the low frequency of outcomes.

RESULTS

Following a rigorous study identification strategy (Fig. 1), a total of only 7 studies could be included for analysis, comprising 372 patients submitted to endovascular repair for thoracic aortic aneurysms (Table I). Procedures were elective in 79%. Intentional LSA coverage performed in 201 patients (54%) varied from 17.9% to 100.0% in the different studies. LSA was revascularized in 20/201 patients (10%) as a prophylactic procedure for selected cases in 4 studies (varying from 9.1% to 18.2%); in the other 3 studies, prophylactic revascularization of the LSA was not performed at all.

Four studies[5,7,26,27] report only the results observed in patients underwent LSA coverage. According to Table II, 9 patients (4.5%) from 3 studies developed left-arm complications, including SSS ($n = 1$), mild effort claudication ($n = 1$), and symptoms of ischemia and/or claudication ($n = 7$). Only one among 201 patients (0.5%) had to be submitted to postoperative revascularization of LSA because of left-arm symptoms (SSS).

Type II endoleaks from the subclavian artery were observed and treated intraoperatively in 5 of a series of 23 patients (21.7%). Other 4 type II endoleaks from the subclavian artery were reported and

Table I. Characterization of the included studies

Studies	Design	Mean follow-up (months)	*N*	Elective procedures	LSA coverage		Prophylatic revascularization of LSA	
					n	%	*n*	%
Tiesenhausen et al., 2003[5]	Prospective	18 ± 14	13	13	3	23.1	0	0.0
Rehders et al., 2004[6]	Retrospective	24 ± 15.8	39	39	7	17.9	0	0.0
Melissano et al., 2005[11]	Retrospective	23 ± 17	30	30	23	76.7	3	13.0
Caronno et al., 2006[7]	Prospective	19 ± 8	3	3	3	100.0	0	0.0
Galili et al., 2007[27]	Prospective	32 ± 15	30	29	11	36.7	2	18.2
Chad Hughes et al., 2010[25]	Retrospective	23 ± 17	79	55	33	41.8	4	12.1
Baba et al., 2015[26]	Retrospective	27 ± 9	178	121	121	68.0	11	9.1

2 of them required postoperative embolization of LSA, totalizing a rate of 1.0% in 201 patients treated with intentional LSA coverage (Table III).

DISCUSSION

This attempt to systematically review the literature regarding the necessity of postoperative revascularization of LSA because of left-arm complications or endoleaks from the subclavian artery preferentially in elective endovascular repair of thoracic aortic aneurysms with intentional coverage of LSA was quite a challenge but even so allowed us to compile some specific information from scientific production.

Most of the studies dealing with LSA coverage during thoracic endovascular aortic repair (TEVAR), with or without prior prophylactic revascularization of LSA, include different pathologies of the thoracic aorta as a whole and generally do not report results for each pathology. Other point is that outcomes most of the time refer to the main neurological complications including strokes and SCI,[13–22] without emphasizing left-arm complications. In a relatively recent study, Klocker et al.[9] studied specifically the functional status of the left arm in 138 patients (73 with LSA coverage) with different pathologies of the thoracic aorta, and only 1 patient treated for a degenerative aneurysm required secondary revascularizations of LSA due to left-arm ischemia, that is, 1.4% of the patients with LSA coverage, but this rate was not clear regarding the cases of aneurysms.

In a systematic review developed by Rizvi et al.[19] including 51 studies published between 1996 and 2008 and comparing outcomes from TEVAR with and without LSA coverage, 9.5% of the patients with LSA coverage had reported left-arm complications (ischemia, claudication, and SSS) against 2.0% of those without LSA coverage. Again, there is no clear information on the findings for each specific pathology of thoracic aorta, on the type of procedures (elective, emergent, and urgent), and on prophylactic LSA revascularization. However, these authors reported a baseline risk of arm ischemia of 2.0% in patients who underwent LSA coverage during TEVAR for aneurysm but is not informed if it required postoperative revascularization.

The rate of arm complications has been reported at 18.5% in patients with bilateral patent vertebrobasilar junctions treated without preventive SLA revascularization in the management of different thoracic aortic pathologies[28] and at 36% in endovascular repair of traumatic descending thoracic aortic transection.[29] In 201 patients submitted to endovascular repair for thoracic aortic aneurysms with LSA

Table II. Outcome: left-arm complications

Study	Left-arm complications			Postoperative revascularization of LSA	
	n	%	Complication	*n*	%
Tiesenhausen et al., 2003[5]	1	33.3	Subclavian steal syndrome	1	33.3
Rehders et al., 2004[6]	0	0		0	0
Melissano et al., 2005[11]	0	0		0	0
Caronno et al., 2006[7]	0	0		0	0
Galili et al., 2007[27]	1	9.1	Mild effort claudication	0	0
Chad Hughes et al., 2010[25]	0	0		0	0
Baba et al., 2015[26]	7	5.8	Ischemia and/or claudication	0	4.1

Table III. Outcome: type II endoleaks

Study	Endoleaks (II)		Need of treatment		
	n	%	*n*	%	Treatment
Tiesenhausen et al., 2003[5]	0	0	—	—	
Rehders et al., 2004[6]	0	0	—	—	
Melissano et al., 2005[11]	5	21.7	5	20.0	Prevertebral ligature of the vessel intraoperatively
Caronno et al., 2006[7]	0	0	—	—	
Galili et al., 2007[27]	0	0	—	—	
Chad Hughes et al., 2010[25]	1	3.3	1	3.0	Coil embolization
Baba et al., 2015[26]	3	2.4	1	0.8	Coil embolization

coverage reported in the studies included in this review, the rate of arm complications was 4.5%. Maybe such divergent rates could be result of mixing findings regarding different pathologies. The way how authors consider an arm complication to be reported can also influence such divergent rates. In a study involving 111 patients electively submitted to SLA coverage without revascularization (most of them treated for a type B dissection), Si et al.[30] applied a linear model for preoperative characteristics, intraoperative LSA coverage, and postoperative symptoms and could conclude that arm ischemia may be associated not only with LSA coverage but also with personal cardiac function.

In this review, we were not able to establish any association between prophylactic revascularization of LSA and arm complications. Anyway, considering the low frequency of arm complications (4.5%) and need of postoperative LSA revascularization (0.5%) in a set of patients mostly not submitted to prophylactic procedures, we can agree with the authors who recommend reserving revascularization of the subclavian artery for patients who develop important complications after TEVAR with LSA coverage in the treatment of aortic aneurysms.[10–12]

Studies reporting the utility of prophylactic revascularization of the LSA before stent graft deployment[3,4] do not effectively justify this prophylactic procedure, except for apparently accepting the myth that ischemic damage or symptoms are inevitable when the LSA ostium is covered.[6]

Four of the studies here reviewed[11,25–27] refer specifically to thoracic aortic aneurysms involving 347 patients. Intentional LSA coverage was performed in 188 (54.2%) patients, and only in 20 (5.8%) patients, LSA was prophylactically revascularized. Postoperative revascularization due to arm complications was not necessary for any patient.

Based on their findings and on the accumulating literature, Galili et al.[27] understood that prophylactic revascularization prior to endovascular repair of thoracic aortic aneurysms should be emphatically reserved to selected cases, especially when the coverage of the descending aorta is extensive because the risk of paraplegia increases without the prophylactic revascularization of LSA. According to Baba et al.,[26] however, LSA revascularization cannot be established as preventive procedure neither for SCI and stroke because the evidence found is still unclear and has been performed more often than necessary.

In the set of patients here analyzed, 1.0% needed secondary intervention of LSA due to type II endoleaks from the subclavian artery, but these findings were not discussed by the authors. The fact is that

reintervention of LSA seems to be rather a consequence of endoleaks from subclavian artery than of left-arm complications. Peterson et al.[24] reported their experience with endovascular repair of type II endoleaks associated with a covered LSA after thoracic endovascular aortic repairs. They reported a rate of 7.6% of postoperative type II endoleaks from LSA in 66 patients with different thoracic pathologies, which is very higher than the 2.0% observed in this review emphasizing aneurysms repair.

An important limitation to this study is the lack of a substantial number of standardized studies clearly demonstrating and comparing arm complications in the endovascular repair of different thoracic aortic pathologies, with or without LSA coverage, with or without prophylactic revascularization of LSA, with or without necessity of a secondary intervention. Available studies refer to only level IV evidence.

Many studies do not detail clinical data, present heterogeneity in the type of intervention (elective, urgent, and emergent), and report the total prevalence of outcomes of interest without specifying the group in which these outcomes occurred, what results in an impossibility of good systematic reviews with more rigorous statistical analysis.

CONCLUSION

Low-quality evidence suggests very low rates of arm complications with the need of LSA revascularizations and of type II endoleaks requiring embolization in elective endovascular treatment of thoracic aortic aneurysms with intentional coverage of LSA without prophylactic revascularization of LSA.

REFERENCES

1. Volodos NL, Karpovich IP, Shekhamin VE, et al. A case of distant transfemoral endoprosthesis of the thoracic artery using a self-fixing synthetic prosthesis in traumatic aneurysm. Grudn Khir 1988;6:84–6.
2. Dake MD, Miller DC, Semba CP, et al. Transluminal placement of endovascular stentgrafts for the treatment of descending thoracic aortic aneurysms. N Engl J Med 1994;331:1729–34.
3. Schoder M, Grabenwoger M, Holzenbein T, et al. Endovascular repair of the thoracic aorta necessitating anchoring of the stent graft across the arch vessels. J Thorac Cardiovasc Surg 2006;131:380–7.
4. Zamor K, Eskandari MK, Rodriguez HE, et al. Outcomes of thoracic endovascular aortic repair and subclavian revascularization techniques. J Am Coll Surg 2015;221:93–100.
5. Tiesenhausen K, Hausegger KA, Oberwalder P, et al. Left subclavian artery management in endovascular repair of thoracic aortic aneurysms and aortic dissections. J Card Surg 2003;18:429–35.
6. Rehders TC, Petzsch M, Ince H, et al. Intentional occlusion of the left subclavian artery during stent-graft implantation in the thoracic aorta: risk and relevance. J Endovasc Ther 2004;11:659–66.
7. Caronno R, Piffaretti G, Tozzi M, et al. Intentional coverage of the left subclavian artery during endovascular stent graft repair for thoracic aortic disease. Surg Endosc 2006;20:915–8.
8. Preventza O, Eheatley GH, Williams J, et al. Can the left subclavian artery be safely covered during endovascular repair of the descending thoracic aorta? Innovations 2008;3:147–50.
9. Klocker J, Koell A, Erlmeier M, et al. Ischemia and functional status of the left arm and quality of life after left subclavian artery coverage during stent grafting of thoracic aortic diseases. J Vasc Surg 2014;60:64–9.
10. Criado FJ, Abul-Khoudoud OR, Domer GS, et al. Endovascular repair of the thoracic aorta: lessons learned. Ann Thorac Surg 2005;80:857–63.
11. Melissano G, Civillini E, Bertoglio L, et al. Endovascular treatment of aortic arch aneurysm. Eur J Vasc Endovasc Surg 2005;29:131–8.
12. Riesenman PJ, Farber MA, Mendes RR, et al. Coverage of the left subclavian artery during thoracic endovascular aortic repair. J Vasc Surg 2007;45:90–4.
13. Buth J, Harris PL, Hobo R, et al. Neurologic complications associated with endovascular repair of thoracic aortic pathology: incidence and risk factors. A study from the European collaborators on stent/graft techniques for aortic aneurysm repair (EUROSTAR) Registry. J Vasc Surg 2007;46:1103–11.
14. Melissano G, Tshomba Y, Bertoglio L, et al. Analysis of stroke after TEVAR involving the aortic arch. Eur J Vasc Endovasc Surg 2012;43:269–75.
15. Maldonado TS, Dexter D, Rockman CB, et al. Left subclavian artery coverage during thoracic endovascular aortic aneurysm repair does not mandate revascularization. J Vasc Surg 2013;57:116–24.
16. Patterson BO, Holt PJ, Nienaber C, et al. Management of the left subclavian artery and neurologic complications after thoracic endovascular aortic repair. J Vasc Surg 2014;60:1491–8.
17. Contrella BN, Sabri SS, Tracci MC, et al. Outcomes of coverage of the left subclavian artery during endovascular repair of the thoracic aorta. J Vasc Interv Radiol 2015;26:1609–14.
18. Cooper DG, Walsh SR, Sadat U, et al. Neurological complications after left subclavian artery coverage during thoracic endovascular aortic repair: a systematic review and meta-analysis. J Vasc Surg 2009;49:1594–601.
19. Rizvi AZ, Murad MH, Fairman RM, et al. The effect of left subclavian artery coverage on morbidity and mortality in patients undergoing endovascular thoracic aortic interventions: a systematic review and meta-analysis. J Vasc Surg 2009;50:1159–69.
20. Sepehripour AH, Ahmed K, Vecht JA, et al. Management of the left subclavian artery during endovascular stent grafting for traumatic aortic injury: a systematic review. Eur J Vasc Endovasc Surg 2011;41:758–69.
21. Sobocinski J, Patterson BO, Karthikesalingam A, et al. The effect of left subclavian artery coverage in thoracic endovascular aortic repair. Ann Thorac Surg 2016;101:810–7.
22. Waterford SD, Chou D, Bombien R, et al. Left subclavian arterial coverage and stroke during thoracic aortic endografting: a systematic review. Ann Thorac Surg 2016;101:381–9.

23. Parmer SS, Carpenter JP, Stavropoulos SW, et al. Endoleaks after endovascular repair of thoracic aortic aneurysm. J Vasc Surg 2006;44:447–52.
24. Peterson MD, Wheatley GH, Kpodonu J, et al. Treatment of type II endoleaks associated with left subclavian artery coverage during thoracic aortic stent grafting. J Thorac Cardiovasc Surg 2008;136:1193–9.
25. Chad Hughes G, Lee SM, Daneshmand MA, et al. Endovascular repair of descending thoracic aneurysms: results with ''on-label'' application in the post Food and Drug Administration approval era. Ann Thorac Surg 2010;90:83–9.
26. Baba T, Ohki T, Kanaoka Y, et al. Clinical outcomes of left subclavian artery coverage on morbidity and mortality during thoracic endovascular aortic repair for distal arch aneurysms. World J Surg 2015;39:2812–22.
27. Galili O, Fajer S, Eyal A, et al. Left subclavian artery occlusion by thoracic aortic stent graft: long-term clinical and duplex follow-up. Isr Med Assoc J 2007;9:668–70.
28. Lee M, Leedo Y, Kim MD, et al. Selective coverage of the left subclavian artery without revascularization in patients with bilateral patent vertebrobasilar junctions during thoracic endovascular aortic repair. J Vasc Surg 2013;57:1311–6.
29. Antonello M, Menegolo M, Maturi C. Intentional coverage of the left subclavian artery during endovascular repair of traumatic descending thoracic aortic transection. J Vasc Surg 2013;57:684–90.
30. Si Y, Fu W, Liu Z, et al. Coverage of the left subclavian artery without revascularization during thoracic endovascular repair is feasible: a prospective study. Ann Vasc Surg 2014;28:850–9.